

CORRESPONDENCE

Open Access



# Central venous catheterization: the cephalic vein access

Shouyin Jiang<sup>1,2,3,4\*</sup>, Yehua Shen<sup>5,6</sup> and Xiaogang Zhao<sup>1,2,3,4</sup>

## Dear Editor,

Establishment and the choice of appropriate location of central venous line can be occasionally very difficult for critically ill patients [1]. Body weight, occurrence of clavicular fracture, infection risk and so on are determinant factors with regard to the location choice of cannulation [2, 3].

A severely injured 81-year-old obese woman (body mass index of 28) was presented to the Emergency Intensive Care Unit (EICU) due to multiple organ failure (neural, respiratory, cardiac, circulatory, renal). She developed severe acute respiratory distress syndrome (ARDS) quickly after injury insult. Due to persistent acute renal insufficiency during EICU stay, she also received continuous renal replacement therapy (CRRT) through percutaneous catheterization of the left internal jugular vein. Thirteen days after admission, she required to change the right supraclavicular central venous line due to continuous vasopressor support and invasive hemodynamic management for heart failure and ARDS. Because there was no other appropriate route, we decided to insert the cannulation through the right cephalic vein, which was measured at 0.28 cm in diameter under ultrasound. The

cannulation was successfully performed guided by ultrasound through the Seldinger technique, with the inserted length of 20 cm suitable for monitoring of central venous pressure (Fig. 1). Daily bedside ultrasound did not detect thrombosis within the cephalic vein.

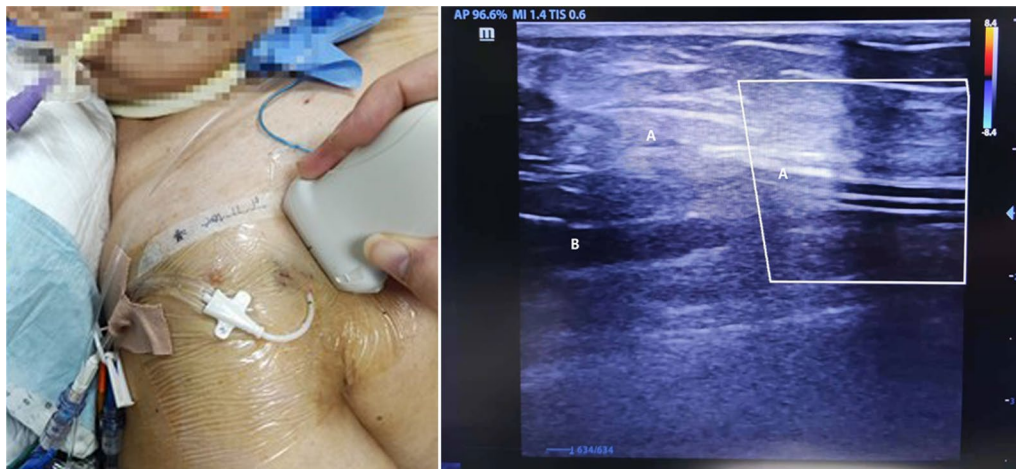
There has been no case report in the literature introducing percutaneous catheterization of central venous catheter through cephalic vein access. However, the cephalic vein access has been used extensively for cardiac implantable electronic device placement through venesection with acceptable complication rates [4, 5]. The cannulation operation under guided by ultrasound can be easier in increased intrathoracic pressure due to venous filling. Our case demonstrated that the cephalic vein approach for central venous catheterization is safe without injury to artery, thorax, and nerve, which should be considered in selected critical care patients (e.g., cannulation difficult due to morbid obesity with no proper puncture site while still require monitoring the central venous pressure).

\*Correspondence: jansoean@zju.edu.cn

<sup>1</sup> Department of Emergency Medicine, The Second Affiliated Hospital, Zhejiang University School of Medicine, Hangzhou 310009, China  
Full list of author information is available at the end of the article



© The Author(s) 2022. **Open Access** This article is licensed under a Creative Commons Attribution 4.0 International License, which permits use, sharing, adaptation, distribution and reproduction in any medium or format, as long as you give appropriate credit to the original author(s) and the source, provide a link to the Creative Commons licence, and indicate if changes were made. The images or other third party material in this article are included in the article's Creative Commons licence, unless indicated otherwise in a credit line to the material. If material is not included in the article's Creative Commons licence and your intended use is not permitted by statutory regulation or exceeds the permitted use, you will need to obtain permission directly from the copyright holder. To view a copy of this licence, visit <http://creativecommons.org/licenses/by/4.0/>. The Creative Commons Public Domain Dedication waiver (<http://creativecommons.org/publicdomain/zero/1.0/>) applies to the data made available in this article, unless otherwise stated in a credit line to the data.



**Fig. 1** Puncture site for the cephalic vein access (left). Double track sign represents the central venous line (right). A, cephalic vein; B, axillary vein

**Acknowledgements**

Not applicable.

**Author contributions**

SJ, YS, and GZ designed the paper. All authors participated in drafting and reviewing. All authors read and approved the final manuscript.

**Funding**

None.

**Availability of data and materials**

The datasets used and/or analyzed during the current study are available from the corresponding author on reasonable request.

**Declarations**

**Ethics approval and consent to participate**

Not applicable.

**Consent for publication**

The authors declare to have informed consent of the patient to publish the image.

**Competing interests**

The authors have disclosed that they do not have any conflicts of interest.

**Author details**

<sup>1</sup>Department of Emergency Medicine, The Second Affiliated Hospital, Zhejiang University School of Medicine, Hangzhou 310009, China. <sup>2</sup>Key Laboratory of the Diagnosis and Treatment of Severe Trauma and Burn of Zhejiang Province, Hangzhou, China. <sup>3</sup>Zhejiang Province Clinical Research Center for Emergency and Critical Care Medicine, Hangzhou, China. <sup>4</sup>Research Institute of Emergency Medicine, Zhejiang University, Hangzhou 310009, China. <sup>5</sup>Department of Radiology, Children’s Hospital, Zhejiang University School of Medicine, Hangzhou, China. <sup>6</sup>National Clinical Research Center for Child Health, Hangzhou, China.

Received: 13 May 2022 Accepted: 23 May 2022

Published online: 08 June 2022

**References**

1. Corradi F, Guarracino F, Santori G, Brusasco C, Tavazzi G, Via G, Mongodi S, Mojoli F, Biagini RUD, Isirdi A, et al. Ultrasound localization of central

vein catheter tip by contrast-enhanced transthoracic ultrasonography: a comparison study with trans-esophageal echocardiography. *Crit Care*. 2022;26(1):113.

2. Patel N, Petersen TL, Simpson PM, Feng M, Hanson SJ. Rates of venous thromboembolism and central line-associated bloodstream infections among types of central venous access devices in critically ill children. *Crit Care Med*. 2020;48(9):1340–8.

3. Pittiruti M, Pinelli F. Recommendations for the use of vascular access in the COVID-19 patients: an Italian perspective. *Crit Care*. 2020;24(1):269.

4. Su J, Kusumoto FM, Zhou X, Elayi CS. How to perform extrathoracic venous access for cardiac implantable electronic device placement: Detailed description of techniques. *Heart Rhythm*. 2022 (in press).

5. Wu CF, Fu JY, Wen CT, Chiu CH, Hsieh MJ, Liu YH, Liu HP, Wu CY. Long-term results of a standard algorithm for intravenous port implantation. *J Pers Med*. 2021;11(5):344.

**Publisher’s Note**

Springer Nature remains neutral with regard to jurisdictional claims in published maps and institutional affiliations.

**Ready to submit your research? Choose BMC and benefit from:**

- fast, convenient online submission
- thorough peer review by experienced researchers in your field
- rapid publication on acceptance
- support for research data, including large and complex data types
- gold Open Access which fosters wider collaboration and increased citations
- maximum visibility for your research: over 100M website views per year

**At BMC, research is always in progress.**

Learn more [biomedcentral.com/submissions](https://biomedcentral.com/submissions)

