

RESEARCH LETTER

Open Access



# Feasibility and safety of watershed detection by contrast-enhanced ultrasound in patients receiving peripheral venoarterial extracorporeal membrane oxygenation: a prospective observational study

Nina Buchtele<sup>1</sup>, Thomas Staudinger<sup>1</sup>, Michael Schwameis<sup>2\*</sup>, Christian Schörghofer<sup>3</sup>, Harald Herkner<sup>2</sup>, Alexander Hermann<sup>1</sup> and UltraECMO investigators

**Keywords:** Extracorporeal membrane oxygenation, Contrast media, Ultrasonography, Feasibility studies

## Background

In bifemoral venoarterial extracorporeal membrane oxygenation (VA ECMO), the transition point at which the antegrade pulsatile output from the left ventricle and the retrograde non-pulsatile ECMO output collide is referred to as watershed [1]. Currently, no standard method is available to determine its location. Occasionally, contrast-enhanced computed tomography (CT) or angiography has been used [1–3]. Both techniques, however, bear disadvantages including radiation exposure and use of iodinated contrast media. We assessed the feasibility and safety of contrast-enhanced ultrasound (CEUS) to detect the watershed at the bedside in patients on bifemoral VA ECMO at three ICUs of a European tertiary care facility.

## Methods

CEUS was performed as soon as possible after ECMO-initiation (Cardiohelp, Maquet, Germany) using SonoVue contrast media (Bracco, Italy). Transesophageal echocardiography (x7-2t probe) and transabdominal

sonography (3–5 MHz curvilinear probe) were performed concomitantly to display mid-esophageal aortic valve, ascending, descending aorta, and upper esophageal aortic arch long-axis views as well as longitudinal views of the proximal (below diaphragm), mid (level of renal arteries), and distal (above iliac bifurcation) abdominal aorta. The mechanical index was set to 0.05–0.10 field of view. Prior to CEUS, the arterial bubble sensor activating zero-flow mode was disabled. The acoustic alarm was kept active. The presence or absence of pulsatility in the left radial artery was documented.

One milliliter of SonoVue was administered via the venous drainage cannula, followed by a flush of 10 ml normal saline. The obtained images were evaluated qualitatively. If a watershed area was not able to be visualized, contrast-enhanced blood flow was classified into “pulsatile” or “continuous” to discriminate between cardiac and ECMO blood flow. The feasibility of CEUS was assessed based on qualitative image evaluation, the amount of contrast media administered, and the rate of bubble detection. Secondary outcomes were safety and frequency of radial arterial pulsatility. Safety variables included ECMO settings, hemodynamics, and neurologic assessment and were obtained over a 6-h period after CEUS.

\* Correspondence: [michael.schwameis@meduniwien.ac.at](mailto:michael.schwameis@meduniwien.ac.at)

<sup>2</sup>Department of Emergency Medicine, Medical University of Vienna, Währinger Gürtel 18-20, 1090 Vienna, Austria

Full list of author information is available at the end of the article



© The Author(s). 2020 **Open Access** This article is licensed under a Creative Commons Attribution 4.0 International License, which permits use, sharing, adaptation, distribution and reproduction in any medium or format, as long as you give appropriate credit to the original author(s) and the source, provide a link to the Creative Commons licence, and indicate if changes were made. The images or other third party material in this article are included in the article's Creative Commons licence, unless indicated otherwise in a credit line to the material. If material is not included in the article's Creative Commons licence and your intended use is not permitted by statutory regulation or exceeds the permitted use, you will need to obtain permission directly from the copyright holder. To view a copy of this licence, visit <http://creativecommons.org/licenses/by/4.0/>. The Creative Commons Public Domain Dedication waiver (<http://creativecommons.org/publicdomain/zero/1.0/>) applies to the data made available in this article, unless otherwise stated in a credit line to the data.

The variables are presented as absolute values (*n*), relative frequencies (%), and median (25–75% IQR). We used random-effects general linear regression models to estimate mean changes for each safety variable (mean ± SD).

**Results**

Between August 2018 and April 2019, ten patients were enrolled (Table 1). Qualitative detection of watershed location by CEUS was feasible using 1 ml contrast media. In five patients, the watershed could be clearly shown in the abdominal aorta, seconds after contrast media

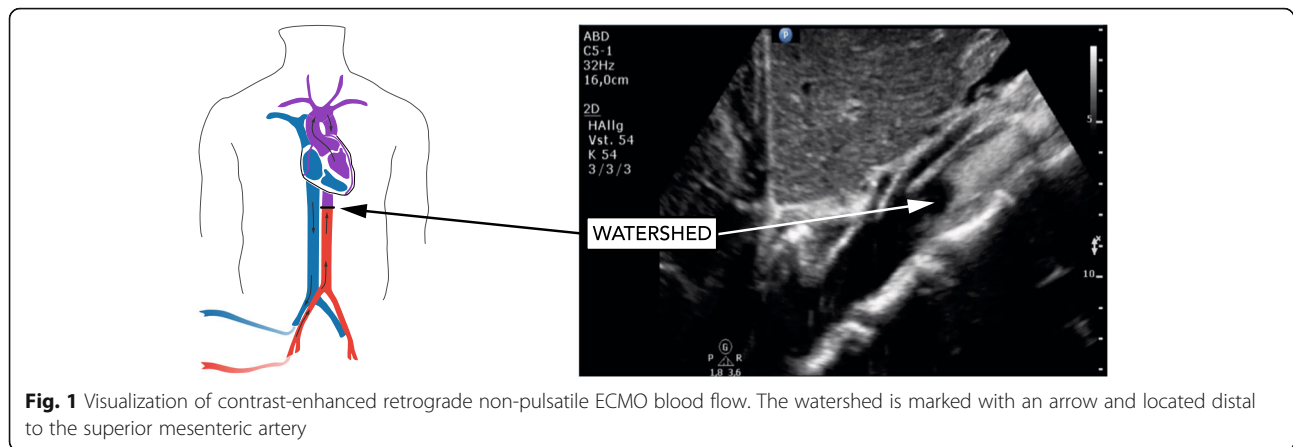
administration (Fig. 1). In the remaining five patients, contrast-enhanced continuous blood flow was visible throughout the abdominal and thoracic aorta indicating watershed location close to the aortic root. The pulsatility of the left radial arterial waveform and opening of the aortic valve was present in all patients. Acoustic bubble detection occurred in all patients after CEUS. No changes in the safety variables related to CEUS occurred (Table 1). CT imaging of the brain (8/10 patients) showed no cerebral lesions suggesting particle embolism.

**Table 1** Baseline characteristics and changes of safety variables from baseline to 6 h after contrast media application

<b>Baseline characteristics</b>					
Male sex	9 [90]				
Age (years)	52 (50–55)				
Reason for ECMO					
Refractory cardiac arrest	6 [60]				
Cardiogenic shock	4 [40]				
Presence of severely impaired left ventricular systolic function	10 [100]				
Time from ECMO start to study inclusion (days), min to max	0–1				
Successful ECMO weaning	5 [50]				
Good neurologic outcome (CPC 1–2)	3 [30]				
Post-oxygenator paO <sub>2</sub> after contrast-enhanced ultrasound (mmHg)	489 (439–507)				
<b>Safety parameters</b>					
Variable	Baseline (n = 10)	5 min (n = 10)	15 min (n = 10)	2 h (n = 9)	6 h (n = 8)
Ventilator FiO <sub>2</sub> (%)	48 (40–80)	48 (40–80)	48 (40–80)	55 (45–80)	48 (40–70)
Peak pressure (mbar)	19.5 (18–21)	19 (18–21)	19 (18–21)	20 (19–23)	18 (18–23)
MAP (mmHg)	73 (70–81)	73 (64–93)	73 (64–93)	77 (73–82)	82 (74–94)
Norepinephrine (µg/kg/min)	0.34 (0.209–0.670)	0.250 (0.148–0.480)	0.250 (0.148–0.480)	0.420 (0.190–0.620)	0.410 (0.142–0.715)
Heart rate (bpm)	97 (66–111)	91 (64–107)	90 (64–107)	80 (61–105)	95 (72–107)
Pump speed (rpm)	2776 (2530–3151)	2698 (2530–3000)	2698 (2530–3000)	2741 (2530–3000)	3050 (2590–3300)
Blood flow (l/min)	2.23 (1.61–2.90)	2.13 (1.58–2.63)	2.13 (1.58–2.63)	2.37 (1.70–2.80)	2.76 (2.10–3.31)
New-onset pupil dilation and/or anisocoria	0	0	0	0	0
	SD overall	SD within	Mean change (95% confidence interval)		p value*
Ventilator FiO <sub>2</sub> (%)	23.72	8.59	– 3.39 (– 7.54 to 0.75)		0.109
Peak pressure (mbar)	3.71	1.11	0.44 (– 0.63 to 1.51)		0.420
MAP (mmHg)	13.32	8.31	– 1.03 (– 8.31 to 6.25)		0.781
Norepinephrine (µg/kg/min)	0.32	0.15	– 0.23 (– 0.18 to 0.13)		0.774
Heart rate (bpm)	25.84	5.68	– 0.87 (– 5.68 to 3.93)		0.721
Pump speed (rpm)	1305.51	159.90	0.67 (– 86.46 to 87.80)		0.988
Blood flow (l/min)	0.84	0.41	0.073 (– 0.15 to 0.29)		0.512

Data are *n* [%] or median (25–75% IQR), unless indicated otherwise. For the random-effects general linear regression models, means with standard deviations were calculated. During the observation period, no changes in hemodynamic values, vasopressor dose, respirator, and ECMO settings occurred in temporal relationship to SonoVue administration. Two patients had already dilated pupils at the time of ultrasound study. Both patients died during the 6-h observation period following a decision to withdraw treatment by the treating physician  
CPC cerebral performance category, ECMO extracorporeal membrane oxygenation, FiO<sub>2</sub> fraction of inspired oxygen, MAP mean arterial pressure, SD standard deviation

\*Results from random-effects general linear regression model



**Fig. 1** Visualization of contrast-enhanced retrograde non-pulsatile ECMO blood flow. The watershed is marked with an arrow and located distal to the superior mesenteric artery

## Discussion

This study assessed the feasibility of CEUS for watershed detection at the bedside in patients on bifemoral VA ECMO. CEUS was apparently safe and provided real-time assessment of the watershed or contrast-enhanced continuous blood flow in the aorta. Increasing evidence indicates that CEUS is safe in critically ill patients, and application areas are ever-expanding [4–6]. In bifemoral VA ECMO, CEUS may help to identify patients at risk for differential hypoxia, given that left radial arterial pulsatility was present in all study patients, including those in whom the watershed was located near the aortic root.

## Limitations

Transthoracic suprasternal echocardiography may be useful to localize the watershed in the aortic arch but has not been tested. Furthermore, no reference imaging technique has been used to assess the performance of CEUS, because no standard method for the detection of the watershed is available, and no repeated measurements were performed.

## Abbreviations

CEUS: Contrast-enhanced ultrasound; CT: Computed tomography; VA ECMO: Venoarterial extracorporeal membrane oxygenation

## Acknowledgements

We gratefully thank our collaborators Gerhard Ruzicka, Christoph Weiser, Hans Domanovits, Alexander O. Spiel, Peter Schellongowski, Andja Bojic, Anne Merrelaar, and Monika Schmid for their valuable help with patient recruitment, performing ultrasound and study flow throughout the study. We thank Sarah Ely for the thorough revision of the manuscript.

## Authors' contributions

NB, MS, and TS designed the study. NB, MS, CS, and AH enrolled the study patients and/or performed the ultrasound. NB, MS, and CS collected the data together with the trained study nurses. NB, MS, and TS analyzed and interpreted the data. HH did the statistical analysis. NB and MS wrote the first draft of the manuscript and drew the figure and table. All authors critically revised the manuscript for important intellectual content and approved its current version. All authors agreed to be accountable for all aspects of the work in ensuring that questions related to the accuracy or integrity of any part of the work are appropriately investigated and resolved. The manuscript has not been previously published and is not under consideration for

publication in the same or substantially similar form in any other peer-reviewed media.

## Funding

This study was supported by the Austrian Society for Internal Medicine and General Intensive Care and Emergency Medicine (ÖGIAM).

## Availability of data and materials

The datasets analyzed during the current study are available from the corresponding author on reasonable request. Complete results from safety data are available with the main manuscript. Exemplary ultrasound loops are available from the corresponding author on request.

## Ethics approval and consent to participate

The study was approved by the Ethics Committee of the Medical University of Vienna (EC#1177/2018) and conducted in accordance with Helsinki Declarations. According to Austrian law regulations, prior to the study enrolment, a waiver was obtained and patients were informed about their participation after regaining consciousness.

## Consent for publication

Not applicable

## Competing interests

The authors declare that they have no competing interests.

## Author details

<sup>1</sup>Department of Medicine I, Intensive Care Unit 13i2, Medical University of Vienna, Vienna, Austria. <sup>2</sup>Department of Emergency Medicine, Medical University of Vienna, Währinger Gürtel 18-20, 1090 Vienna, Austria. <sup>3</sup>Department of Clinical Pharmacology, Medical University of Vienna, Vienna, Austria.

Received: 3 March 2020 Accepted: 23 March 2020

Published online: 02 April 2020

## References

- Hoepfer MM, Tudorache I, Kuhn C, Marsch G, Hartung D, Wiesner O, et al. Extracorporeal membrane oxygenation watershed. *Circulation*. 2014;130(10):864–5.
- Napp LC, Brehm M, Kuhn C, Schafer A, Bauersachs J. Heart against venoarterial ECMO: competition visualized. *Int J Cardiol*. 2015;187:164–5.
- Lambert L, Grus T, Balik M, Fichtl J, Kavan J, Belohlavek J. Hemodynamic changes in patients with extracorporeal membrane oxygenation (ECMO) demonstrated by contrast-enhanced CT examinations - implications for image acquisition technique. *Perfusion*. 2017;32(3):220–5.
- Bennett CE, Tweet MS, Michelena HI, Schears GJ, Mulvagh SL. Safety and feasibility of contrast echocardiography for ECMO evaluation. *JACC Cardiovasc Imaging*. 2017;10(5):603–4.

5. Fine NM, Abdelmoneim SS, Dichak A, Kushwaha SS, Park SJ, Mulvagh SL. Safety and feasibility of contrast echocardiography for LVAD evaluation. *JACC Cardiovasc Imaging*. 2014;7(4):429–30.
6. Harrois A, Grillot N, Figueiredo S, Duranteau J. Acute kidney injury is associated with a decrease in cortical renal perfusion during septic shock. *Crit Care*. 2018;22(1):161.

### **Publisher's Note**

Springer Nature remains neutral with regard to jurisdictional claims in published maps and institutional affiliations.

**Ready to submit your research? Choose BMC and benefit from:**

- fast, convenient online submission
- thorough peer review by experienced researchers in your field
- rapid publication on acceptance
- support for research data, including large and complex data types
- gold Open Access which fosters wider collaboration and increased citations
- maximum visibility for your research: over 100M website views per year

**At BMC, research is always in progress.**

Learn more [biomedcentral.com/submissions](https://biomedcentral.com/submissions)

